

A Fragile Balance - Autoimmunity and Blistering in Pemphigus Vulgaris

¹Ruparelia Pritesh B., Professor and HOD, Department of OMR, College of Dental Sciences and Research Centre, Bopal

²Panchal Kaxika M., M.D.S Part 3 - PG Student, Department of OMR, College of Dental Sciences and Research Centre, Bopal

³Patel Manali M., Senior Lecturer, Department of OMR, College of Dental Sciences and Research Centre, Bopal

⁴Modi Pavan K., M.D.S Part 1-PG Student, Department of OMR, College of Dental Sciences and Research Centre, Bopal

Correspondence Author: Panchal Kaxika M., M.D.S Part 3 - PG Student, Department of OMR, College of Dental Sciences and Research Centre, Bopal.

How to Cite This Article: Ruparelia Pritesh B., Panchal Kaxika M., Patel Manali M., Modi Pavan K., “A Fragile Balance - Autoimmunity and Blistering in Pemphigus Vulgaris”, IJDSDR – January – February – 2026, Vol. – 5, Issue – 1, P. No. 08 – 11.

Open Access Article: This is an Open Access article that uses a funding model which does not charge readers or their institutions for access and distributed under the terms of the Creative Commons Attribution License (<http://creativecommons.org/licenses/by/4.0>) and the Budapest Open Access Initiative (<http://www.budapestopenaccessinitiative.org/read>), which permit unrestricted use, distribution, and reproduction in any medium, provided original work is properly credited.

Type of Publication: Case Report

Conflicts of Interest: Nil

Abstract

Pemphigus refers to a rare group of autoimmune diseases that can be potentially life threatening, characterized by the formation of blisters followed by erosions on the skin and mucous membranes. While a genetic predisposition contributes to the development of autoantibodies responsible for the condition, the exact trigger that initiates the cascade of immune response remains unknown. In here, we report a case of 46-year old male patient suffering from Pemphigus Vulgaris emphasizing the significance of clinical examination, pertinent investigations, treatment rendered and its outcome.

Keywords: Autoimmune, Blister, Oral mucosa, Pemphigus.

Introduction

Wichman (1791) formulated the term ‘Pemphigus’, stemmed from a Greek word ‘pemphix’, meaning a blister; which is a characteristic of the disease.¹ The most common form is pemphigus vulgaris, accounting for over 80% of cases, with 0.5 – 3.2 cases per million annually. In India, it ranges from 0.09% to 1.8%, with higher prevalence in women (F:M ~ 2:1) especially during 5-6th decade of life.^{2,3}

The intraepithelial lesions in Pemphigus Vulgaris are caused by IgG autoantibodies binding to desmogleins, leading to loss of cell adhesion which results in the

separation of cells and the formation of intraepithelial bullae.² Oral lesions usually precede the skin lesions.⁴ HLA alleles DRB1 1401/04 and DQB1*0503 are linked to Pemphigus Vulgaris in individuals of European or Asian ancestry.⁵

Case Report

A 46-year-old male residing in Ahmedabad, reported to the Department of OMR with complaint of recurrent ulcers in mouth since 5 months. Patient had no relevant family history, medical history or any known allergy.

On extraoral examination, erosions along large denuded areas were seen in axillae, neck, scalp and groin region. Irregular ulcers along with pseudo-membrane were seen on upper and lower lip. On intraoral examination, diffuse ragged erosions were present bilaterally on buccal mucosa. Similar diffuse and irregular erosions were also present on palate, gingiva, tongue and upper – lower labial mucosa with pseudo-membrane at certain sites and erythematous periphery [Figure 1]. Nikolsky's sign was positive.

Following examination, provisional diagnosis of allergic stomatitis was given; with differential diagnosis of recurrent aphthous stomatitis, erythema multiforme, bullous lichen planus, pemphigus, pemphigoid and epidermolysis bullosa.

Diagnostic Assessment

Haematological investigations were performed. Cytological smear showed swollen cells with degenerated 'Tzanck cells' along with lymphocytes, with a normal nucleus. Patient was then referred to a dermatologist who took a skin biopsy from right arm. Histopathological examination revealed epidermis with supra basal vesicles filled with acantholytic cell and hemorrhagic material. Dermis revealed foci of mild perivascular mononuclear inflammatory cells infiltrate. Direct immunofluorescence (DIF) revealed squamous

intercellular substance deposition with immunoglobulin G (IgG), showing 'lace like pattern'. [Figure 2]

Therapeutic Intervention

The patient was given symptomatic treatment which comprised of levocetirizine 5mg o.d., antibiotic (amoxicillin 500mg + clavulanic acid 125mg) t.i.d. for 5 days, multivitamin for 1 month, Calcium and vitamin D3 combination b.i.d for 15 days, fluconazole 150mg o.d. for 3 days, 0.1% triamcinolone acetonide b.i.d for 15 days and 0.15% benzydamine gargles b.i.d for 15 days. Following biopsy, patient was prescribed with oral prednisolone 20mg b.i.d, cetrimide solution 5% w/v (shampoo) and 2% mupirocin ointment for 15 days by dermatologist.

After 15 days, 50% reduction in erosions and erythema along with symptoms were noted. After 1 month, 90-95% improvement was seen [Figure 3], after which the dose of prednisolone was gradually tapered to 10mg. Over past 4 months, patient was on remedial therapy and so far, no new lesions have been reported.

Discussion

Pemphigus being a potentially life threatening mucocutaneous disorder typically presenting as a thin walled, flaccid blister on normal skin or mucosa, spreading into large eroded areas.⁶ 'Nikolsky's sign' and 'Asboe- Hansen Sign (bulla spread phenomenon)', are characteristic features of Pemphigus Vulgaris.^{2,7}

Baker J and Seiffert-Sinha K in 2022, reported three cases of clinically and histologically confirmed pemphigus vulgaris without history of mucosal lesions and just cutaneous lesions. Two patients lacked the most common PV-associated HLA alleles, DRB1*0402 and DQB1*0503. These same patients also tested negative for the primary PV-related autoantibodies, anti-desmoglein 3 and anti-desmoglein 1, despite being in an active disease state.⁸

Chen J et al. in 2023, reported a rare case of non-healing gingival ulcer for three months and later on histopathological examination and DIF revealed to be pemphigus vulgaris.⁹

Rai A et al. in 2015, reported a case with ulcers in mouth and difficulty in swallowing since 20 days. Later it was diagnosed to be pemphigus vulgaris and due to early diagnosis, lower doses for a short period of time was able to control the disease.⁶

Early diagnosis is a critical component of patient management. The primary treatment includes systemic corticosteroids, followed by azathioprine, mycophenolate mofetil (MMF), dapsone, methotrexate, cyclophosphamide, cyclosporine, IVIG and rituximab. Pulsed therapy has been used in the management of recalcitrant lesions.¹⁰ In untreated condition, mortality rate ranges from 50-100% because of extensive skin involvement, loss of epidermal barrier function leading to electrolyte imbalance and secondarily bacterial or systemic infection.

Conclusion

Pemphigus Vulgaris being an autoimmune blistering dermatosis with a chronic course requires prompt diagnosis and effective management to avoid severe complications. Ongoing clinical trials exploring FcRn inhibitors, Bruton tyrosine kinase (BTK) inhibitors and T- cell co-stimulation blockers offer promising avenues for more precise, personalized and safer interventions. As our understanding of the disease mechanism evolves, these novel therapies pave the path for improved outcomes and quality of life in patients with pemphigus vulgaris.

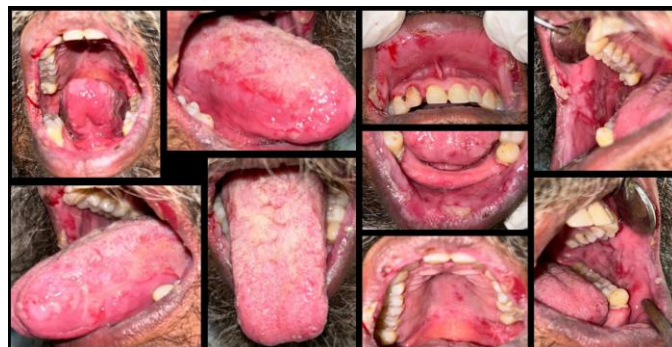

Figure 1: Diffuse ragged erosions involving bilateral buccal mucosa, labial mucosa, lips, tongue and palate with pseudo-membrane at certain sites and erythematous periphery.

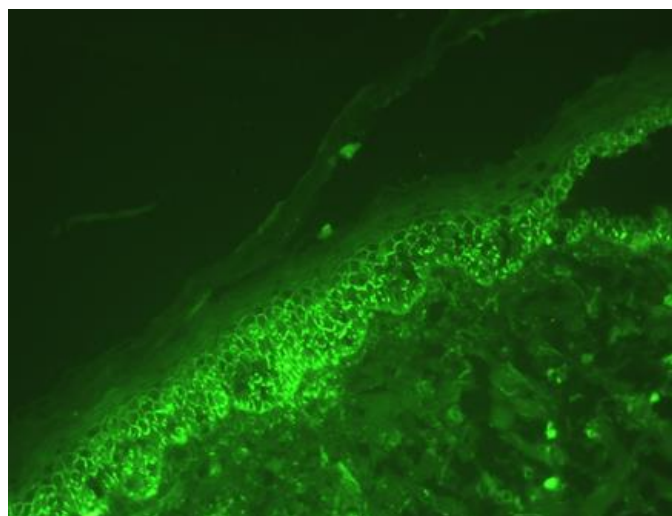


Figure 2: Direct immunofluorescence microphotograph showing deposition of IgG at intercellular spaces of epidermis and 'Chicken wire appearance' (20x).

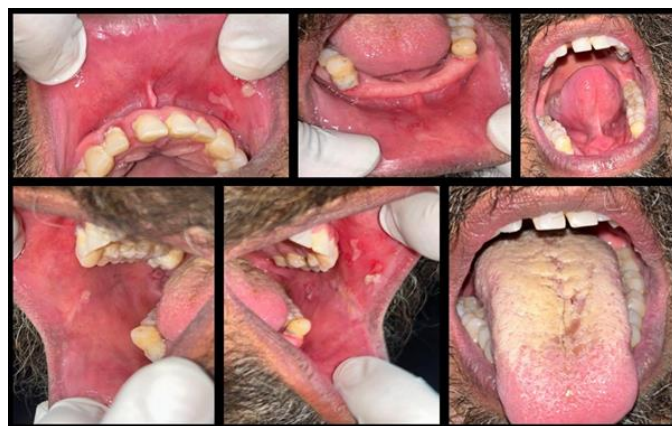

Figure 3: Follow up after 1 month showing, 90-95% regression of erosions in oral mucosa.

References

1. Rajendran R. Shafer's textbook of oral pathology. Elsevier India; 2009.
2. Glick M. Burket's oral medicine. PMPH USA; 2015.
3. Marinović B, Miše J, Jukić IL, Bukvić Mokos Z. Pemphigus—the crux of clinics, research, and treatment during the COVID-19 pandemic. *Biomedicines*. 2021 Oct 28;9(11):1555.
4. Dagistan S, Goregen M, Miloglu O, Çakur B. Oral pemphigus vulgaris: a case report with review of the literature. *Journal of oral science*. 2008;50(3):359-62.
5. Lombardi ML, Mercurio O, Pirozzi G, Manzo C, Lombardi V, Ruocco V, Schiavo AL, Guerrera V. Common human leukocyte antigen alleles in pemphigus vulgaris and pemphigus foliaceus Italian patients. *Journal of investigative dermatology*. 1999 Jul 1;113(1):107-10.
6. Rai A, Arora M, Naikmasur V, Sattur A, Malhotra V. Oral pemphigus vulgaris: case report. *Ethiopian journal of health sciences*. 2015 Oct 5;25(4):637-372.
7. Ongole R, Praveen BN, editors. Textbook of oral medicine, oral diagnosis and oral radiology e-book. Elsevier Health Sciences; 2021 Apr 13.
8. Baker J, Seiffert-Sinha K, Sinha AA. Case report: Documentation of cutaneous only pemphigus vulgaris without history of mucosal lesions in North America. *Frontiers in Immunology*. 2022 Sep 8;13:969279.
9. Chen J, Tang H, Zhang D, Tang Y, Li W, Liu G, Liu B. A rare case of pemphigus vulgaris disguised as a malignant gingival ulcer. *BMC Oral Health*. 2023 May 23;23(1):319.
10. Kridin K. Pemphigus group: overview, epidemiology, mortality, and comorbidities. *Immunologic research*. 2018 Apr;66(2):255-70.