

Apically extruded sealers: Assessment of apical healing and sealer dissolution of extruded sealers and their effect on treatment outcome

¹Noha K. Zeidan, Department of Orthodontics, Faculty of Dentistry, Alexandria University, Champollion St., Azarita, Alexandria, Egypt

Correspondence Author: Noha K. Zeidan, Department of Orthodontics, Faculty of Dentistry, Alexandria University, Champollion St., Azarita, Alexandria, Egypt.

How to Cite This Article: Noha K. Zeidan, “Apically extruded sealers: Assessment of apical healing and sealer dissolution of extruded sealers and their effect on treatment outcome”, IJDSDR – September – October - 2022, Vol. – 1, Issue - 1, P. No. 19 – 25.

Open Access Article: This is an Open Access article that uses a funding model which does not charge readers or their institutions for access and distributed under the terms of the Creative Commons Attribution License (<http://creativecommons.org/licenses/by/4.0>) and the Budapest Open Access Initiative (<http://www.budapestopenaccessinitiative.org/read>), which permit unrestricted use, distribution, and reproduction in any medium, provided original work is properly credited.

Type of Publication: Original Research Article

Conflicts of Interest: Nil

Abstract

Aim: This retrospective study is aimed to assess the apical healing and resorption of sealer in cases where there has been inadvertent extrusion of Endoflas FS (ZOE based) and Sealapex (Calcium-hydroxide based), as well as how they affect treatment outcome.

Materials and Methods: 30 patients (n=15 for Sealapex sealer and n=15 for Endoflas FS sealer) exhibiting sealer extrusion in immediate post obturation radiographs were included in this present study. Recall radiographs were taken after 6 months and 1 year and were compared with the previous immediate post obturation radiographs to evaluate apical healing and the extent of resorption of the sealer material.

Statistics: Pearson's Chi Square test was used for this study.

Results: At 6 month follow up, better healing was shown by Endoflas FS as compared to Sealapex with statistically non-significant difference. Apical healing for both Sealapex and Endoflas FS progressed with time. Sealer resorption was slightly higher in case of Endoflas FS than Sealapex with statistically non-significant difference.

Conclusion: In case of periapical extrusion, both Sealapex (Calcium hydroxide based sealer) and Endoflas FS (ZOE based sealer) did not affect the treatment outcome.

Keywords: Endodontic treatment, Sealer extrusion, Obturation, Apical healing, Sealer resorption.

Introduction

It is crucial for the clinician to have a thorough understanding of root canal morphologies in order to

provide optimal endodontic treatment. The purpose of endodontic treatment is to completely clean the root canal system and eliminate the infection from the tooth. Root canal filling material should remain confined to the apex of the root. At times, as a result of overinstrumentation of the canals, there is a possibility of extrusion of sealers, irrigation solutions or even micro-organisms beyond the root apex into the neighbouring periapical tissues.

Root canal obturation restricts the flow of fluids from peri-radicular tissues into the canals as well as micro-organisms and their by-products from the canals to the peri-radicular tissues.

In accordance with the guidelines approved by Comitato Intersocietario Coordinamento delle Associazioni Odontostomatologiche Italiane in the year 2003, a small amount of endodontic material beyond the apex of the root could be considered admissible only if it does not cause insult to vitally important structures such as maxillary sinus and inferior alveolar nerve. As long as the material is soluble in the tissue fluids, resorbable, biocompatible and the surrounding area is clear of infection, the peri-radicular tissues can tolerate small amounts of extrusion. The apically extruded filling materials might hinder or impede the healing process of teeth exhibiting apical periodontitis. The sealer is responsible for sealing accessory canals, defects within the canals and inconsistencies between the filling materials and the canal walls³. Root canal sealer is used along with core root canal filling material e.g. Gutta percha.

Materials And Method

The cases included in the study are treated by the author using a standardized treatment protocol over a period of one year. Informed consent was obtained from all patients. Inclusion criteria were single and multirouted

teeth diagnosed clinically with chronic apical periodontitis with apical radiolucencies, confirmed radiographically. The patients included in the study did not have any systemic or immunological diseases which might affect the healing process.

The teeth included in the study are a part of (n=127) teeth from 98 patients treated by the author, over a period of 12 months. (n=50) teeth from 43 patients showed apical sealer extrusion in the immediate post-obturation radiographs.

30 patients (n=15 for Sealapex sealer and n=15 for Endoflas FS sealer) with one year recall radiographs were selected for the analysis of the study. The procedure followed: Local anaesthesia was administered (2% lignocaine and adrenaline 1:200,000; Lox, Neon Laboratories. The standardized root canal treatment protocol was performed using a strict aseptic technique with rubber dam isolation (Hygenic Dental Dam, Coltene Whaledent Inc., Germany). Coronal flaring was done with Gates Glidden burs (Dentsply Maillefer, Switzerland) and apical patency was checked with #10 K-file (Mani Inc., Japan). The working length was established 1mm short of the root apex as indicated by the electronic apex locator (MM Control, Micro Mega, France) and confirmed by working length radiographs. Different rotary systems were used for Crown down preparation (Protaper Gold, Dentsply Maillefer, Switzerland; Hero shaper, Micro Mega, France; GenEndo NiTi Rotary, Coltene Whaledent Pvt. Ltd. France). Overinstrumentation was avoided. Irrigation was frequently done using copious amounts of 2ml of 3% NaOCl with a #30 gauge side vented needle followed by final rinse with 5ml of distilled water. All teeth were treated in two visits with an interappointment calcium hydroxide medication for 7 days. Obturation was done using Lateral compaction technique of gutta

percha and sealer. The sealers used were Endoflas FS (Sanlor, Colombia) and Sealapex (Sybron Endo, USA). All immediate Post-obturation radiographs were taken using conventional method with films (E-Speed, Carestream Dental, NY, USA) with parallel cone technique. The radiographic parameters were standardized (Genoray EZX-60, portable X-RAY, Korea). Access restoration was done using Glass Ionomer Cement (3M ESPE, USA).

Follow UP Examination

For follow up examination, one periapical radiograph was taken for every patient using standardized conventional straight cone projection technique. Comparison between immediate post obturation radiographs and recall radiographs was done blindly by an examiner endodontist. Two main points of comparison were targeted, Apical healing and sealer resorption. If periodontal ligament space showed normal width and contour and surrounding radiolucency changes into normal appearing bone, these factors indicated that the periapical tissue was healthy. Categories for Apical healing : No Healing, Incomplete Healing, Completely Healed. (6 month and 1 year follow up radiographs were taken) Evaluation of sealer resorption was based on the presence/absence of apically extruded sealer material. Categories for Sealer resorption: Non-resorbed sealer, Partially resorbed sealer, Completely resorbed sealer.

Data Analysis

Table 1: Resorption status of extruded sealers (1 year follow up)

		Material		Total	Chi-square value	p value of Chi-square test
		Sealapex	Endoflas FS			
Resorption status (1 year)	CR	6	9	15	1.200	0.549#
	NR	3	2	5		
	PR	6	4	10		
	Total	15	15	30		

Data was obtained and compiled on a MS Office Excel Sheet (version 2019, Microsoft Redmond Campus, Redmond, Washington, United States) and was subjected to statistical analysis with the help of the Statistical package of social sciences (SPSS V 26.0, IBM). Using Chi-square test, frequencies of categories of variables were compared with groups. For all the statistical tests, $p < 0.05$ was considered to be statistically significant, keeping α error at 5% and β error at 20%, thus giving a power to the study as 80%.

* = statistically significant difference ($p < 0.05$)

** = statistically highly significant difference ($p < 0.01$)

= non-significant difference ($p > 0.05$)

Results

Resorption status between groups is depicted using Chi-square test in [Table 1]. Intergroup comparison of frequencies of apical healing for both the sealers at different time intervals using Chi-square test is depicted in [Table 2]. Intragroup comparison of frequencies of apical healing for both sealers at different time intervals using Chi-square test is depicted in [Table 3]. [Fig. 1] shows graphical representation of resorption status for both sealers. [Fig. 2] shows graphical representation of apical healing for both sealers at different time intervals. Radiographic representation of sealer dissolution seen in case of Endoblast FS [Image 1]. Radiographic representation of sealer dissolution seen in case of Sealapex [Image 2].

The frequencies between the groups showed a statistically non-significant difference ($p > 0.05$).

Table2: Inter group comparison of frequencies of apical healing.

		Material		Total	Chi-square value	p value of Chi-square test
		Sealapex	Endoflas FS			
Apical healing (6 months)	CH	5	8	13	1.450	0.484#
	IH	6	5	11		
	NH	4	2	6		
	Total	15	15	30		
Apical healing (1 year)	CH	8	9	17	0.259	0.879#
	IH	4	4	8		
	NH	3	2	5		
	Total	15	15	30		

The frequencies between the groups showed a statistically non-significant difference ($p > 0.05$).

Table 3: Intra group comparison of frequencies of apical healing

		Time		Total	Chi-square value	p value of Chi-square test
		1 year	6 months			
Apical healing (Endoflas FS)	CH	9	8	17	0.170	0.919#
	IH	4	5	9		
	NH	2	2	4		
	Total	15	15	30		
Apical healing (Sealapex)	CH	8	5	13	1.235	0.539#
	IH	4	6	10		
	NH	3	4	7		
	Total	15	15	30		

The frequencies between the groups showed a statistically non-significant difference ($p > 0.05$).

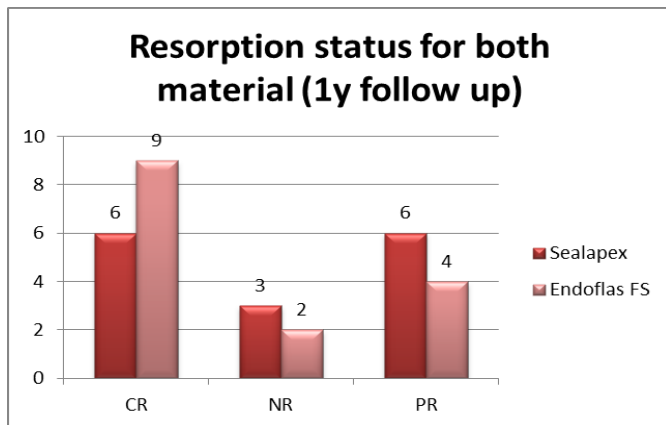


Fig 1: Resorption status (1 year follow up – Sealapex and Endoflas FS)

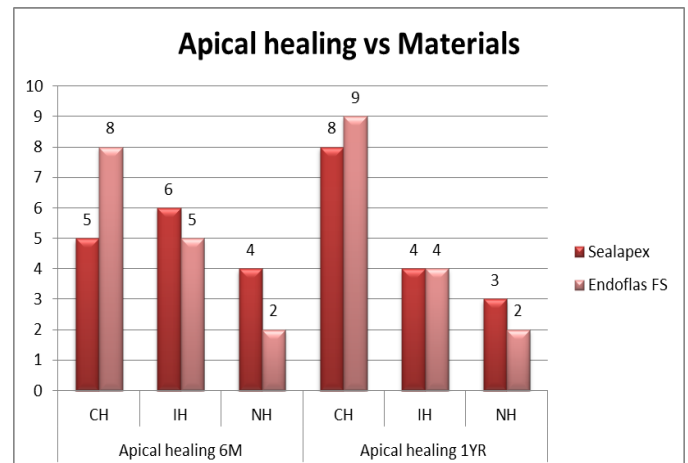
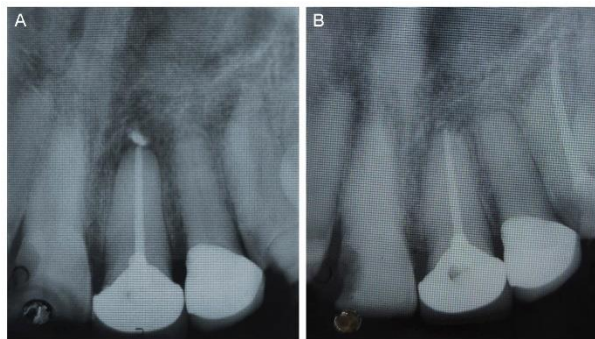


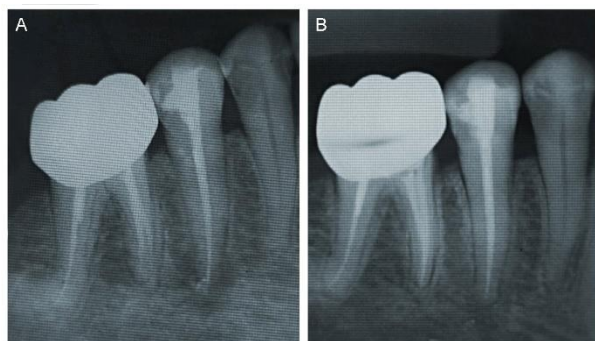
Fig 2: Apical healing (6 months and 1 year) vs material

Fig 3: Representation of sealer resorption with Endoflas FS (1 year follow up)



(A) Post-obturation radiograph. Apically extruded sealer seen. (B) 1 year follow up radiograph. Sealer resorption seen.

Fig 4: Representation of sealer resorption with Sealapex (1 year follow up)



(A) Post-obturation radiograph. Apically extruded sealer seen. (B) 1 year follow up radiograph. Sealer resorption seen.

Discussion

This retrospective study assessed the effects of cases of inadvertent post – obturation apical extrusion of sealers on Apical healing and resorbability of sealers. The European Society of Endodontology (ESE) recommends evaluating the results of endodontic treatment at least one year after completion to determine if the treatment was a success or not. Additionally, ESE highlighted certain findings that determines the success of treatment e.g. No pain or swelling, absence of sinus tract, preservation of function, radiographically normal width and continuity of periodontal ligament space⁵.

After being extruded via the apical foramen, sealers may dissolve in peri-radicular tissues, be phagocytosed or encapsulated by fibrous connective tissue. The material's physio-chemical characteristics, particularly its solubility in water, will determine how it behaves. When considering the material's stability in the interradicular space, this quality may be favourable; nevertheless, if the material is extruded into the peri-radicular tissues, it may not be an ideal property.

Sealapex comes under the widely used Calcium hydroxide based sealers, while Endoflas FS represents the category of ZOE sealers. Overall the results showed that there was not any definite difference between Sealapex and Endoflas FS sealers in terms of apical healing and resorbability of the extruded sealers. Also apical healing was not negatively affected in presence of both Sealapex and Endoflas FS extruded sealers. Moreover, complete apical healing was more evident in case of Endoflas FS during 6m follow up than Sealapex (Fig.2). Whereas, incomplete healing was seen slightly more in case of Sealapex during 6m follow up than Endoflas FS (Fig.2). Apical healing for both Sealapex and Endoflas FS progressed with time. However, compared to Endoflas FS, Sealapex demonstrated a somewhat slower rate of apical healing. Resorbability was slightly higher in case on Endoflas FS than Sealapex (Fig.1).

Freshly mixed sealers possess toxicity which subsides as the sealer sets⁴. Several studies show that sealers eventually lose their irritating potential and then turn inert. Majority of sealers cause momentary inflammatory reactions that go away with time. Even when sealers are retained within the canal space, a variable degree of inflammation typically manifests where the sealers come into contact with the vital apical and peri-radicular tissues.

The infection was found to be more responsible for delayed apical healing or no healing cases rather than overfilling's cytotoxicity. Overinstrumentation can lead to excessive foramen expansion and distortion, makes it challenging to obtain the proper apical adaption of the filling material. Additionally, teeth with apical periodontitis frequently exhibit apical root resorption, which can result in deformations that also impair the quality of the apical filling. When tissue fluids and exudate escape into the canal and reach remaining bacteria to provide a growth substrate, the inadequacy of the apical seal becomes a concern. Additionally, excessive instrumentation always causes debris from necrotic pulp and diseased dentin to be displaced into the peri-radicular tissues. Bacteria embedded in the debris that is inoculated therein may be physically shielded from the host defensive mechanisms, preventing healing. The fact that sealer is not present does not imply that it has entirely dissolved into the peri-radicular tissue. Because radiographs are bi-dimensional, it is possible that the density or volume of the residual sealer was so small that it could not be identified radiographically, but could be proven histologically⁴. Also due to the study's retrospective nature, proper case randomization was not possible.

Conclusion

As long as the root canal system is thoroughly cleaned and obturated, the type of extruded sealer does not greatly alter the treatment outcome. Blatant extrusion of filling material should be prevented as they may give rise to postoperative problems⁷.

References

1. Dalopoulou A, Economides N, Evangelidis V. Extrusion of root canal sealer in periapical tissues: Report of two cases with different treatment management and literature review. *Balkan Journal of Dental Medicine*. 2017;21(1):12-8
2. Santoro V, Lozito P, De Donno A, Grassi FR, Introna F. Extrusion of endodontic filling materials: medico-legal aspects. two cases. *The Open Dentistry Journal*. 2009;3:68.
3. Atteia MH. Apical healing, resorbability, and digital radiodensity after apical extrusion of totalfill versus ah-plus sealers (one-year retrospective study). *Egyptian Dental Journal*. 2017 Oct 1;63(4-October (Fixed Prosthodontics, Dental Materials, Conservative Dentistry & Endodontics)):3717-23.
4. Ricucci D, Rôças IN, Alves FR, Loghin S, Siqueira Jr JF. Apically extruded sealers: fate and influence on treatment outcome. *Journal of endodontics*. 2016 Feb 1;42(2):243-9.
5. Marín-Bauza GA, Silva-Sousa YT, Cunha SA, Rached-Junior FJ, Bonetti-Filho I, Sousa-Neto MD, Miranda CE. Physicochemical properties of endodontic sealers of different bases. *Journal of Applied Oral Science*. 2012;20:455-61.
6. Molina IC, Molina GC, Stanley K, Lago C, Xavier CF, Volpato CA. Partial-prep bonded restorations in the anterior dentition: Long-term gingival health and predictability. A case report. *Quintessence Int*. 2016 Jan;47(1):9-16.
7. Goldstein MB. No-prep/ minimal-prep: the perils of oversimplification. *Dent Today*. 2007;26:10.
8. Lowe RA. No-prep veneers: a realistic option. *Dent Today*. 2010;29:80– 86.
9. Mizrachi M, Lowe RA. A new and economical concept no-prep veneers. *Dent Today*. 2011;30:138,140,142–143.
10. Friedman MJ. Porcelain veneer restorations: a clinician's opinion about a disturbing trend. *J Esthet Restor Dent*. 2001; 13:318–327.

11. Edelhoff D, Sorensen JA. Tooth structure removal associated with various preparation designs for anterior teeth. *J Prosthet Dent.* 2002;87:503–509.
12. Rdaz GM. Minimum thickness anterior porcelain restorations. *Dent Clin North Am.* 2011;55:353–370.
13. Burke FJ. Survival rates for porcelain laminate veneers with special reference to the effect of preparation in dentin: a literature review. *J Esthet Restor Dent.* 2012;24:257–265.
14. Gresnigt M, Ozcan M. Esthetic rehabilitation of anterior teeth with porcelain laminates and sectional veneers. *J Can Dent Assoc.* 2011;77:b143.
15. Hunter AJ, Hunter AR. Gingival margins for crowns: a review and discussion. Part II: Discrepances and configurations. *J Prosthet Dent.* 1990;64:636–642.
16. Balevi B. Limited evidence on the best position for prosthetic margins. *Evid Based Dent.* 2013;14:103–104.
17. Papageorgiou SN, Papadelli AP, Koidis PT, Petridis HP. The effect of prosthetic margin location on caries susceptibility. A systematic review and meta-analysis. *Br Dent J.* 2013;214:617–624.
18. Gurel G, Sesma N, Calamita MA, Coachman C, Morimoto S. Influence of enamel preservation on failure rates of porcelain laminate veneers. *Int J Periodontics Restorative Dent.* 2013;33:31–39.
19. Larson TD. 25 years of veneering: what have we learned? *Northwest Dent.* 2003;82(4):35–39.
20. Al-Wahadni A, Martin DM. Glazing and finishing dental porcelain: a literature review. *J Can Dent Assoc.* 1998;64:580–583.